International Pleural Newsletter

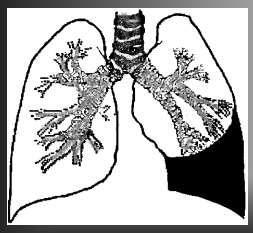

A Publication of the International Pleural Network

Volume 7 Issue 3
July 2009

Editors:
Richard W. Light Nashville, TN, USA
Y.C. Gary Lee Perth, Australia

Co-Editors:
Michael H. Baumann Jackson, MS, USA
Robert J.O. Davies Oxford, UK
John E. Heffner Portland, OR, USA

International Advisors:
P Astoul France
V C Broaddus USA
A Ernst USA
G Hillerdal Sweden
I Kalomenidis Greece
R Loddenkemper Germany
M Noppen Belgium
F Rodriguez-Panadero Spain
S A Sahn USA
L R Teixeira Brazil
C Xie China
D Bouros Greece
T E Eaton New Zealand
F V Gleeson UK
S Idell USA
T K Lim Singapore
S E Mutsaers Australia
J M Porcel Spain
S Romero Canderia Spain
G F Tassi Italy
F S Vargas Brazil
A P C Yim Hong Kong

Administrator: **Emma Hedley** Oxford, UK
emmahedley@orh.nhs.uk

The ***International Pleural Newsletter*** is distributed or web-posted by the:

American College of Chest Physicians
Asian Pacific Society of Respirology
Asociacio n Latino Americana del Torax
Belgian Society of Pulmonology
Brazilian Thoracic Society
British Thoracic Society
Costa Rican Thoracic Society
European Respiratory Society
International Mesothelioma Interest Group
Italian Association of Hospital Pulmonologists
Singapore Thoracic Society
South African Thoracic Society
Thoracic Society of Australia & New Zealand
Turkish Thoracic Society

The ***Newsletter*** is on line:
www.musc.edu/pleuralnews

Guest editor: Dr Ioannis Kalomenidis

✸ ✸ ✸ ✸

European Guidelines for the Management of Malignant Pleural Mesothelioma

Arnaud Scherpereel MD
University Hospital of Lille II, France
a-scherpereel@chru-lille.fr

The incidence of malignant pleural mesothelioma (MPM) is expected to increase for at least the next two decades. Following the guidelines proposed by the French Speaking Society for Chest Medicine (SPLF)[1], the British Thoracic Society (BTS)[2] and the European Society of Medical Oncology (ESMO)[3] published between 2006 and 2008, the European Respiratory Society (ERS) and the European Society of Thoracic Surgeons (ESTS) Task Force brought together experts and prepared a practical and up-to-date guidelines on the management of MPM[4]. The full report will be published soon in the *European Respiratory Journal*. This article presents several highlights of the ERS/ESTS Task Force documents.

To obtain an early and reliable diagnosis of MPM is crucial. The panel recommends that except in patients with contraindications to the procedure or prior pleural symphysis, a thoracoscopy with multiple biopsies should be performed for the diagnosis of MPM. Pathology using standard staining procedures cannot reliably provide the diagnosis in 7-15% of cases. Therefore a diagnosis of MPM should always be based on immunohistochemical examination.

In the absence of a uniform, robust and validated staging system, we advise using the most recent TNM based classification, and we propose a three-step pre-treatment assessment. Performance status of the patient and histopathological subtype are currently the

only prognostic factors of clinical importance in management of MPM. Other potential prognostic parameters (such as those proposed by CALGB and EORTC) should be recorded at baseline and reported in clinical trials. When a decision is made to treat patients with chemotherapy, subjects with good performance status (0-2) should be treated with combination chemotherapy consisting of pemetrexed or raltitrexed, and a platinum-based agent. Immunomodulating agents, targeted biotherapies and vaccines should not be used in the treatment of MPM outside clinical trials. Few patients are candidates for radical surgery (extrapleural pneumonectomy, EPP) which should be performed only within clinical trials, in specialized centers, and as a part of multimodality regimes (including chemotherapy and post-operative radiotherapy). Radiotherapy should not be performed after pleurectomy/decortication, which is not curative but can be considered in some patients for symptom control.

The experts were unable to draw any consensus recommendation on prophylactic radiotherapy against needle tract metastases as the value of this treatment is still debated.

When comparing the previous guidelines[1-3] with the most recent proposal from the ERS/ESTS taskforce[4], there is a clear and remarkable convergence of the recommendations from the experts of the different European scientific societies, despite differences in methods used to draw up the guidelines. We believe that providing clear and homogenous guidelines for the clinicians can improve the management of patients with MPM. We also hope that this can encourage further multicenter randomized clinical trials. Such international initiatives can present exciting prospects, and will be of great interest, for both clinicians and patients with mesothelioma.

References

1. Scherpereel A. Respir Med 2007;101:1265-76.
2. BTS statement on malignant mesothelioma in the UK. Thorax 2007;62 Suppl 2:ii1-ii19.
3. Stahel RA et al. Ann Oncol 2008;19:ii43-4.
4. Scherpereel A, et al. unpublished data (submitted).

If you have any comment on the Newsletter or interesting cases of pleural disease, contact:
Ms Emma Hedley ***emma.hedley@orh.nhs.uk***

Radiographic Measurement of Tumor Load in Pleural Malignancies

Anna K Nowak MBBS PhD FRACP
University of Western Australia, Western Australia.
anowak@meddent.uwa.edu.au

New cancer treatments must be carefully tested in clinical trials, and valid and reliable outcome measures are essential to ensure meaningful results. Radiological assessment of tumor response is an important endpoint and a surrogate for patient benefit, particularly in early phase clinical trials. In later phase studies, objective response rates corroborate the use of survival and quality of life endpoints. Time to tumor progression is an increasingly important endpoint in the era of targeted therapies, and also requires reliable tumor measurement criteria.

The unique location and growth pattern of malignant pleural mesothelioma (MPM) poses challenges for clinicians measuring radiological response. MPM usually grows as a circumferential rind around the interior of the hemithorax, but may also involve the interlobar fissures, infiltrate the mediastinum or chest wall, and be associated with atelectasis and pleural effusion. Earlier tumor measurement criteria were clearly unsuitable for MPM, requiring measurement of bi-dimensionally measurable tumor masses[1], which were often not present or did not represent the major areas of involvement in this disease. More recently, both the original and updated RECIST 1.1 criteria used uni-dimensional measurements for assessment of response, an approach which seemed more suitable for this disease, but which posed numerous problems in application[2-4].

The current accepted measurement criteria for MPM are the 'Modified RECIST Criteria', specific for mesothelioma but also potentially applicable to other pleural malignancies such as metastatic adenocarcinoma[5]. These criteria specify measurement of the pleural tumor perpendicular to the chest wall or mediastinum, in order to assess tumor thickness. Measurements at two reproducible sites on three separate axial CT images at least one centimeter apart were proposed, with the sum of six measurements being the pleural uni-dimensional measurement (Fig 1). Additional uni-dimensional measurements of nodal or metastatic disease may also be taken and

summed as per the RECIST criteria. Definitions of complete and partial response or progressive disease are in keeping with the RECIST criteria, with a 30% decrease in the sum of the uni-dimensional measurements constituting a partial response. Partial response by these criteria correlates with other outcome measures such as overall survival and lung function, making it a valid surrogate for patient benefit[5].

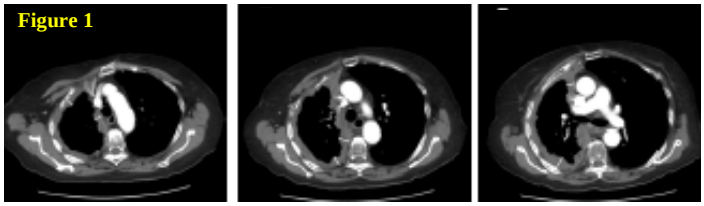

Even with measurement guidelines specific to pleural malignancy, several practical difficulties and key questions remain. Measurement sites in the lower thorax are difficult to reproduce due to respiratory movement and difficulty in identifying the same anatomical location. Nevertheless, this is often a site of bulky disease. Areas of atelectasis or loculated pleural effusion may be falsely assessed as tumor by the inexperienced operator. Written descriptions of tumor measurement site are probably inadequate; measurements taken from computerized radiology systems must be printed in hard copy in order to return to the same pleural area again. It is also unclear what is the minimum tumor thickness that can be measured reproducibly, particularly in a disease where 0.5 cm of circumferential rind represents a substantial disease burden. New technologies such as volumetric CT measurements and FDG-PET scanning[6] are under investigation and may find a place in assessment of response for MPM in the future.

References

1. Miller A et al. Cancer 1981; 47: 207-214.
2. Therasse P et al. JNatl Cancer Inst 2000; 92:205-16.
3. Eisenhauer EA et al. Eur J Cancer 2009; 45: 228-47.
4. van Klaveren RJ et al.Lung Cancer 2004; 43: 63-9.
5. Byrne MJ et al. Ann Oncol 2004; 15: 257-60.
6. Francis RJ et al.. J Nucl Med 2007; 48:1449-58.

Does Right Heart Failure Cause Pleural Effusion?

Richard W. Light MD
Vanderbilt University, Nashville, TN
rlight98@yahoo.com

It is generally accepted that the accumulation of pleural fluid in patients with congestive heart failure (CHF) is due to left ventricular failure rather than right ventricular failure[1,2]. This conclusion is based on the observations that in patients admitted to the coronary care unit, pleural effusions were much more closely associated with elevations in the wedge pressure than in elevations in the pulmonary artery pressure or the right atrial pressure[1] and that pleural effusions were not present in any of 27 patients with pulmonary hypertension even when elevated right atrial pressure was present[2].

However, studies in animals do not support this dogma. In sheep, elevation of the pressure in the superior vena cava leads to the development of pleural effusion[3]. Also, when the systemic venous pressure is increased in dogs by balloon obstruction of the superior and inferior vena cava, pleural effusions develop[4].

It has been my clinical impression that patients with pulmonary hypertension and right heart failure frequently have pleural effusions. We reviewed the charts and radiographs of 147 patients who were diagnosed with idiopathic or familial pulmonary artery hypertension and were treated at our pulmonary hypertension center between 1995 and 2006. Thirty one of the 147 patients (21.1%) had pleural effusions[5]. There were possible alternative explanations for the pleural effusions in ten of them. Most of the pleural effusions in the remaining 21 patients were associated with right heart failure. Nineteen patients were diagnosed as having right heart failure via right heart catheterization, echocardiography or physical exam. As for the two remaining patients with pleural effusion: both had trace bilateral pleural effusions but no obvious symptoms or signs of right heart failure at the time the effusions were present. Of the 19 patients with right heart failure and pleural effusions, eight had ascites and eight had pericardial effusions (two had both).

When the 116 patients without pleural effusion were compared to the 19 patients with pleural

effusion and right heart failure, those with pleural effusions had a significantly higher incidence of both ascites and pericardial effusions. In addition, the right atrial pressure was significantly higher in the patients with the pleural effusions (16.0 ± 6.8 mmHg versus 8.8 ± 5.5 mmHg) although there were no significant differences in the mean pulmonary artery pressure, pulmonary wedge pressure, cardiac output, or pulmonary vascular resistance[5]. The majority of the pleural effusions associated with pulmonary hypertension and right heart failure were small, although seven of the 19 (37%) occupied more that 25% of the hemithorax. The pleural effusions were unilateral right-sided in 11 patients (58%), unilateral left sided in three patients (16%) and bilateral in five patients (26%)[5].

In conclusion, it appears that the animal studies were correct. Isolated right heart failure secondary to pulmonary hypertension can have an associated pleural effusion which at times is sizable. Right heart failure should be considered in the differential diagnosis of a pleural effusion.

References

1. Wiener-Kronish JP, et al. Am Rev Respir Dis 1985; 132: 1253-6
2. Wiener-Kronish JP, et al. Chest 1987; 92: 967-70
3. Allen SJ, et al. Am J Physiol 1988; 255: H492-H495
4. Mellins RB, et al. J Appl Physiol 1970; 29: 564-9
5. Tang K-J, et al. Chest 2009; (in press)

CASE REPORT

A Malignant Pleural Effusion of Unusual Etiology

A 32-year-old man presented with cough and occasional blood-tinged sputum, breathlessness on exertion and pleuritic chest pain of two months duration. Chest x-ray showed a left-sided pleural effusion. In addition, chest CT scan (fig 1) revealed significant consolidation of left lower lobe with hypodense areas that probably represent cystic, hemorrhagic or necrotic regions, as well as focal thickening of the parietal pleura, posteriorly (arrow).

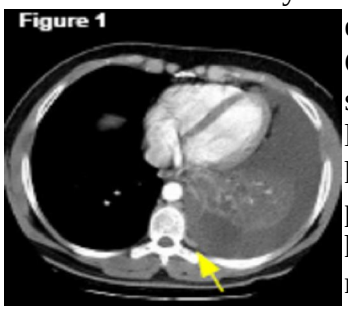

Pleural fluid proved to be a lymphocytic exudate (6190 nucleated cells/μl, 85% lymphocytes, pH 7.40, total protein 5 mg/dL and LDH 306 IU/L), with low ADA levels (21 IU/L). No endobronchial lesion was found during bronchoscopy. Cytology and cultures of pleural fluid, sputum and bronchial aspirate were negative. Video assisted thoracoscopic surgery (VATS) was inconclusive because of the presence of extensive dense adhesions that prevented thorough inspection of the thoracic cavity. Serum and pleural fluid levels of β-hCG were substantially elevated (6350 and >10000 U/L, respectively). A CT guided needle biopsy of the parietal pleural lesions (fig 2) revealed a germ-cell carcinoma.

CT scan of the abdomen, ultrasound of the testis, bone scintigraphy and gastroscopy did not reveal any additional abnormalities.

It is assumed that the patient had a primary pulmonary choriocarcinoma (PPC) with pleural metastases. PPC is an extremely rare tumor characterized by proliferation of syncytial cells and secretion of β-human gonadotropin (β-hCG). It affects young people of either sex though it is more common in women[1]. Measurement of serum/urine levels of β-hCG can aid diagnosis and is useful in follow-up and prognosis of this tumor.

CT-guided fine needle biopsy is a useful tool which, in appropriate circumstances, can represent a valid and minimally invasive intervention to obtain tissue specimens from suspected pleural lesions[2]. It is important to note that, as in the presented case, CT-guided sampling of a pleural lesion can establish the diagnosis when thoracoscopy cannot be performed because of co-morbidities or technical limitations.

References

1. Zapatero J, et al. Scand J Thorac Cardiovasc Surg. 1982;16: 279-81.
2. Mahnken AH, Ricke J (Eds.). CT- and MRI-Guided Interventions in Radiology. Springer-Verlag Berlin. Heidelberg, 2009.

Likourgos Kollilekas MD
University of Athens, Atticon Hospital,
Athens, Greece
lykol@yahoo.gr